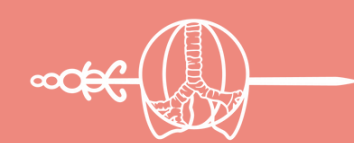

# THE AMAZING CASE RACE

## CASE STUDY 04

2023 ACADEMY

IASLC



INTERNATIONAL  
ASSOCIATION  
FOR THE STUDY  
OF LUNG CANCER

## Complete response to pembrolizumab as monotherapy in a patient with baseline stage IV NSCLC with very high PD-L1 expression

Federica Pecci, MD  
Italy

### LEARNING GOALS

**Goal 1:** Sustained intracranial response to first-line pembrolizumab in the context of NSCLC with very high PD-L1.

**Goal 2:** Prolonged systemic disease control after discontinuation of pembrolizumab in a patient treated almost for three years.

**Goal 3:** Understand the importance of a better stratification of patients with PD-L1 more than 50% for a more tailored treatment selection.

### BACKGROUND

C,C, is a male, 62-year-old with 60 pack-year smoking history.

Following the onset of nonproductive cough and occasional pain in the right hypochondrium, the patient followed up with chest X-ray which described right hilar mass of 8 x 5cm and fracture of the posterior arch of the VI rib.

A CT scan of the chest, abdomen, and CNS were performed, which confirmed adenocarcinoma of the lung and bone and brain metastases.

### CURRENT PRESCRIPTIONS

- Levodropropizine for cough

### COMORBIDITIES/MED HX

- Previous diagnosis of ring cell gastric carcinoma treated with total gastrectomy
- Prostatic hypertrophy

### OVERALL DIAGNOSIS

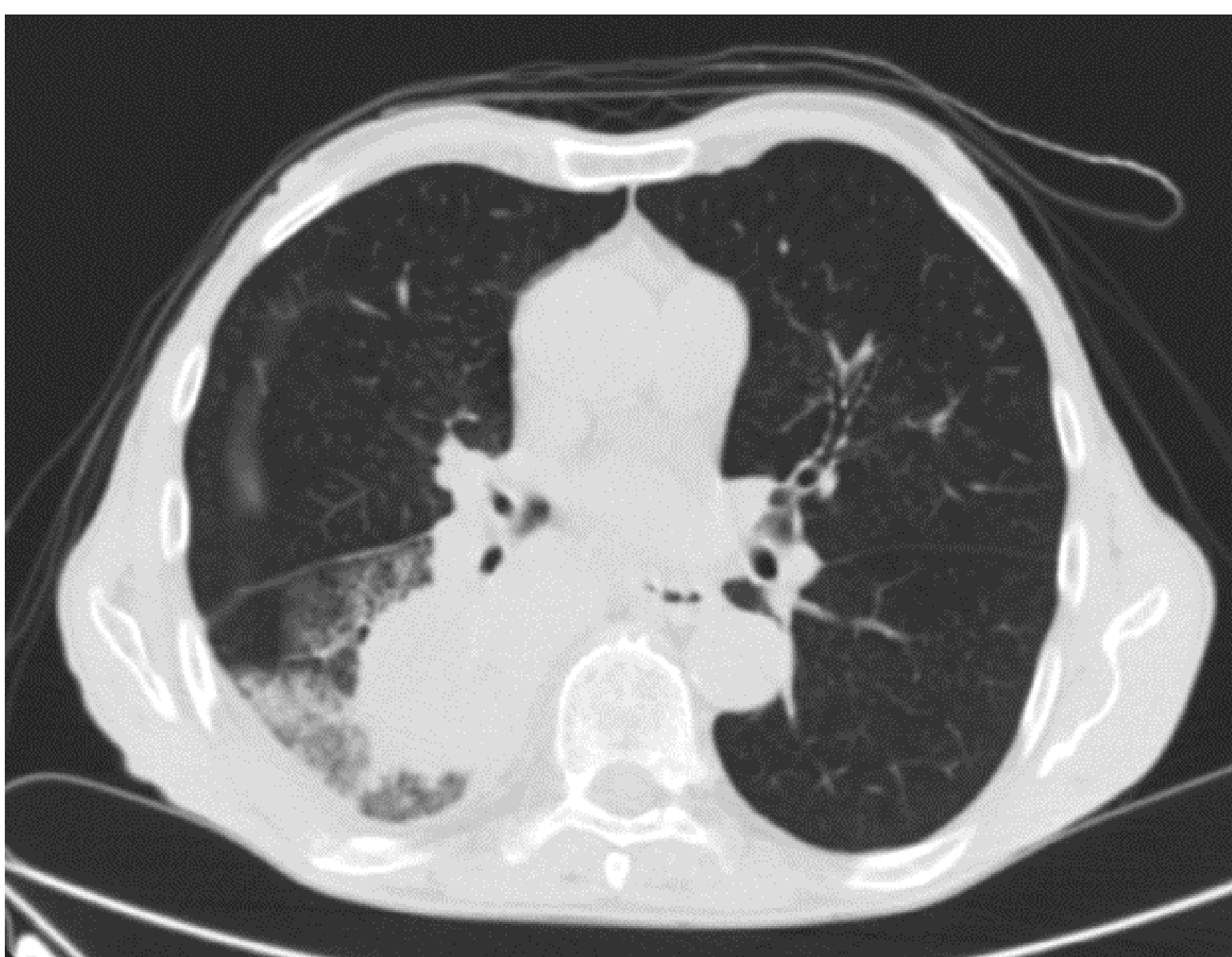
Adenocarcinoma of the lung with bone and brain metastases, PD-L1 TPS 95%.  
The single subcentimetric brain metastasis was asymptomatic.

### TESTING

#### CT SCAN: CHEST

##### Findings:

- Right lower ilo-parailary mass with steno-obstruction of the bronchial branches to the lower lung lobe
- Right pleural effusion with shaded ground-glass opacities of the right lower lobe
- Mediastinal lymphadenomegalies, and lytic osteostructural alteration of the posterior arch of the eighth rib with associated neoformed solid tissue (*Figure 1*).



*Figure 1. Right lower ilo-parailary mass*

## STAGING CONSIDERATIONS

Imaging modalities that are safest in pregnancy Ultrasound and MRI (without contrast). PET CT and CT pelvis are contraindicated with the highest fetal radiation dose. Iodinated contrast could cross the placenta in animal studies but did not show teratogenicity, data in humans are however lacking.

Gestational age also plays a key role, with the fetus being most-sensitive to radiation up to week 16, during which they are at risk of fetal malformations or CNS anomalies. When proper abdominal shielding is employed, imaging should not be withheld if it is necessary for oncological management of patient.

## STAGING SCANS

In this case, the gestational age is 28 weeks (trimester 3). Given minimal risk to the fetus, contrasted CT Thorax and CT brain with abdominal shielding were performed to help stage the patient's cancer.

### CONTRASTED CT BRAIN

Scan was normal.

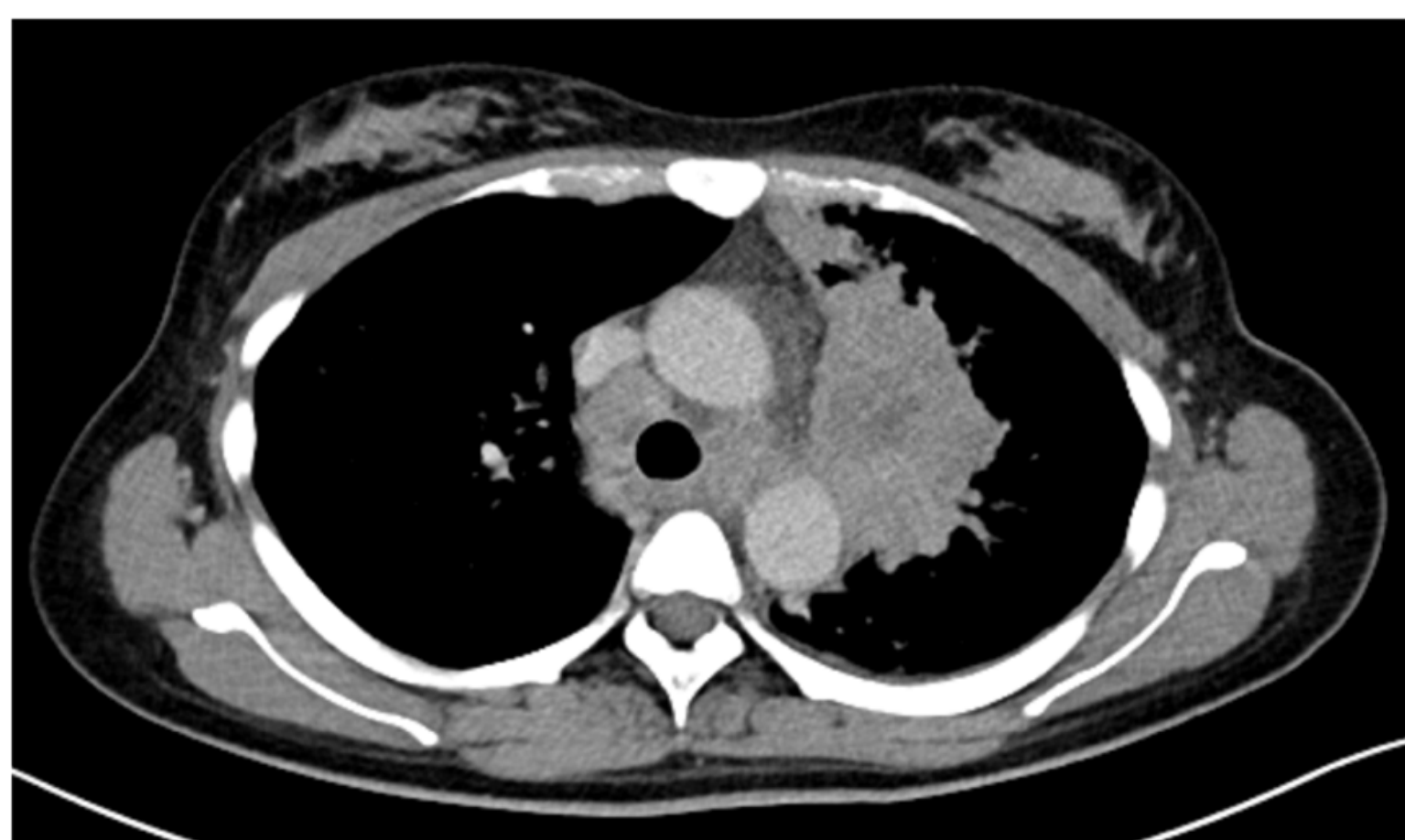

Figure 3

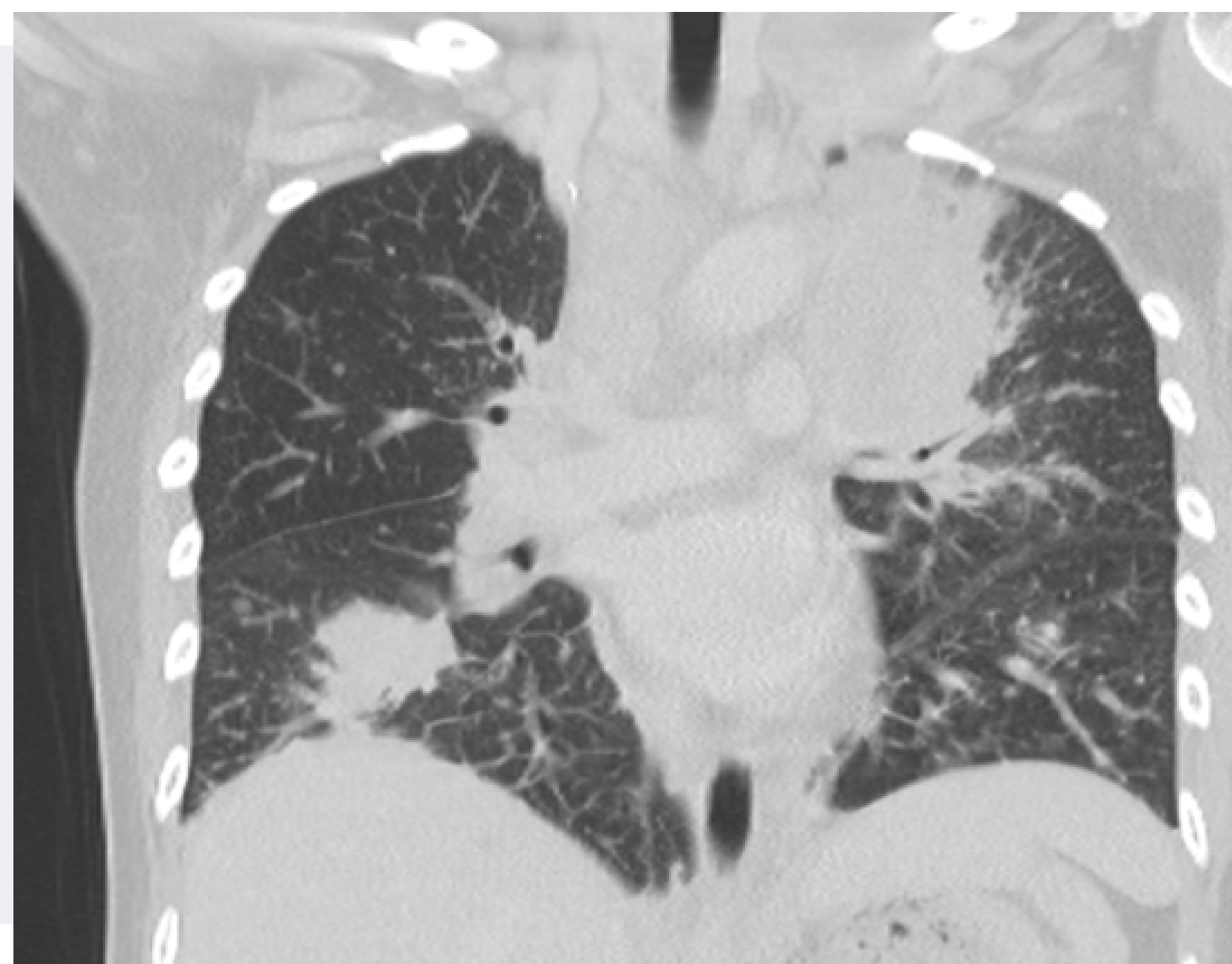

Figure 2

### CONTRASTED CT THORAX

Scan showed an irregular soft tissue mass measuring 9.3 x 4.7 x 7.1 cm seen centered in the upper lobe abutting the mediastinal pleura, involving the left perihilar region and superior segment of left lower lobe with multiple satellite nodules scattered in both lungs. Small left pleural effusion. There are also enlarged mediastinal, left hilar and left supraclavicular lymph nodes..

STAGING

CONSIDERATIONS

# Want to learn more about this case?

**VOTE FOR CASE 04**

### CONTRASTED CT BRAIN

Scan was normal.

Figure 3

### Figure 2

### CONTRASTED CT THORAX

Scan showed an irregular soft tissue mass measuring 9.3 x 4.7 x 7.1 cm seen centered in the upper lobe abutting the mediastinal pleura, involving the left perihilar region and superior segment of left lower lobe with multiple satellite nodules scattered in both lungs. Small left pleural effusion. There are also enlarged mediastinal, left hilar and left supraclavicular lymph nodes..