



Histologic transformation in lung cancer: The crucial role of tissue biopsy

Pedro Rocha, MD, PhD
Spain

LEARNING GOALS

Goal 1: Appreciate the significance of biomarker testing in NSCLC. Select the most suitable test and align it with the corresponding treatment.

Goal 2: Effectively manage treatment expectations.

Goal 3: Make informed decisions for diagnostic workup when there are suspicions of disease progression.

Goal 4: Recognize the importance of excluding placental metastases and monitor for rare occurrence of vertical transmission.

Goal 5: Multidisciplinary management in a tertiary unit with obstetrics and neonatology support is key for successful management of these complex cases.

BACKGROUND

M.C., a 9-year-old female with a 5-pack-year smoking history, sought medical attention during an asymptomatic SARS-CoV-2 infection.

She presented to the ED with a two-week history of progressive shortness of breath, persistent cough, and headaches.

Upon admission to the ED, M.C. underwent a chest X-ray, revealing a substantial left pleural effusion occupying more than half of the left hemithorax.

THE AMAZING CASE RACE

CASE STUDY 06

CURRENT PRESCRIPTIONS

- Acetaminophen 1g every 8 hours
- Levothyroxine 50mcg every 24 hours
- Drospirenone ethinylestradiol 0.3mg/3mg every 24 hours (contraceptive used to prevent pregnancy).

COMORBIDITIES/MED HX

- Hypothyroidism
- Previous surgery: cholecystectomy

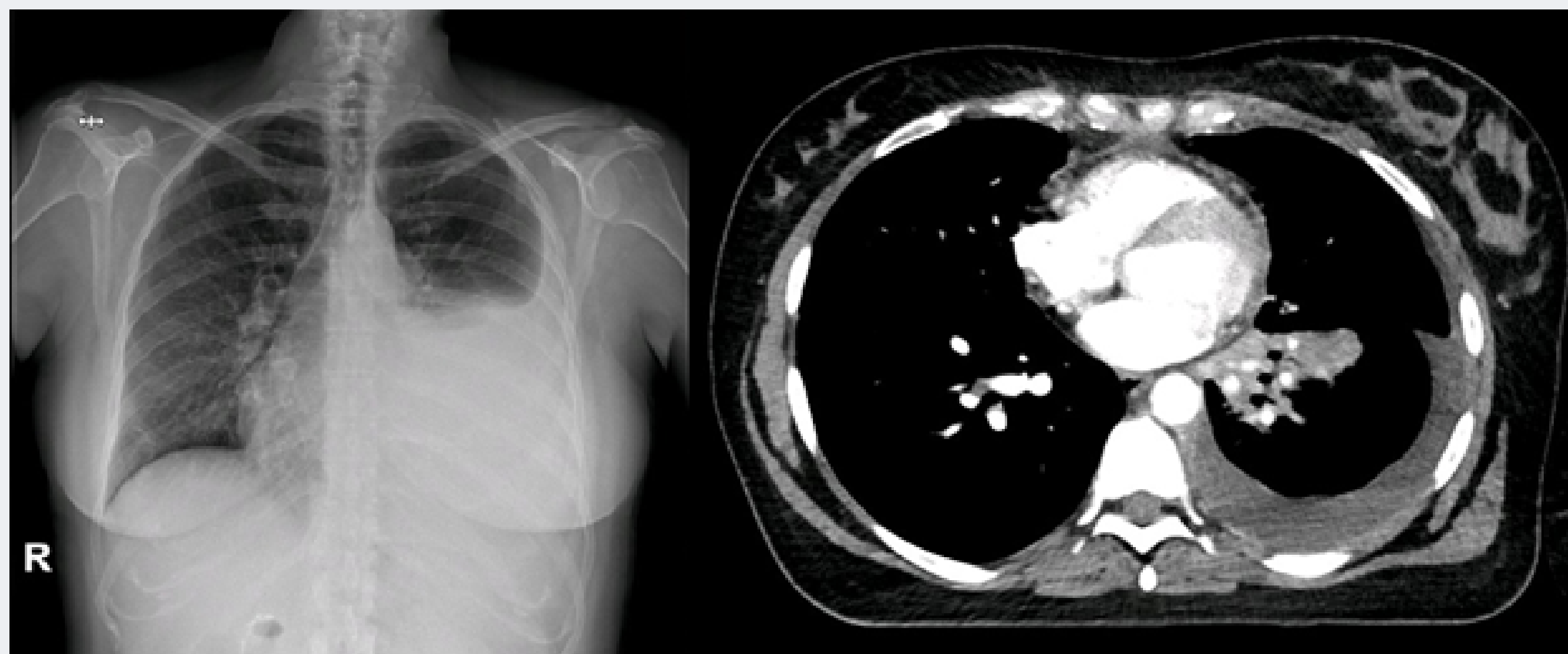
OVERALL DIAGNOSIS

Newly diagnosed lung adenocarcinoma in a pregnant patient, currently at 28 weeks of gestation, with high disease burden.

TESTING

CT imaging disclosed extensive left pleural effusion, accompanied by peribronchovascular thickening extending into the inferior lobe and lingua.

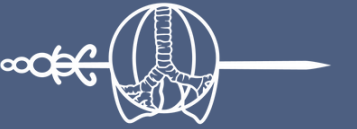Additionally, bilateral hiliomediastinal lymph nodes were observed, measuring greater than 1.5cm in diameter.



THE AMAZING CASE RACE

CASE STUDY 06

IASLC



INTERNATIONAL
ASSOCIATION
FOR THE STUDY
OF LUNG CANCER

ADDITIONAL TESTING

Brain MRI: No lesions suggestive of metastasis are found.

Bone scan: A lesion was observed in the T6 vertebra suggestive of a metastatic lesion.



**Want to learn more
about this case?**

VOTE FOR CASE 06