



## Definitive treatment of bilateral lung cancers with a radiotherapy-based approach

Aditya Juloori, MD  
United States

### LEARNING GOALS

**Goal 1:** Understand radiographic differences between lung cancers.

**Goal 2:** Importance of genomic testing for diagnosis and differentiation of synchronous primary lung cancers.

**Goal 3:** Choosing appropriate workup for stage III NSCLC.

**Goal 4:** Management of bilateral radiotherapy and subsequent follow-up.

### BACKGROUND

Ms. Smith is a 78-year-old female with former history of smoking (100 pack years, quit 19 years ago) without any relevant comorbidities.

---

In early 2021, the patient was found to have lung nodules incidentally on a CT chest. She was asymptomatic.

---

CT reportedly showed bilateral lung I nodules (RML and L lingula) as well as L hilar adenopathy.

---

Patient was referred to medical oncology, radiation oncology, and thoracic surgery.

# THE AMAZING CASE RACE

## CASE STUDY 11



### CURRENT PRESCRIPTIONS

- no relevant medications

### COMORBIDITIES/MED HX

- no relevant medical history

## OVERALL DIAGNOSIS

Suspected advanced lung cancer. Integration of interventional pulmonology for further diagnosis.

Clinical update after biopsies confirmed N2 disease (station 5, station 7) as well as L hilar disease, all c/w adenocarcinoma.

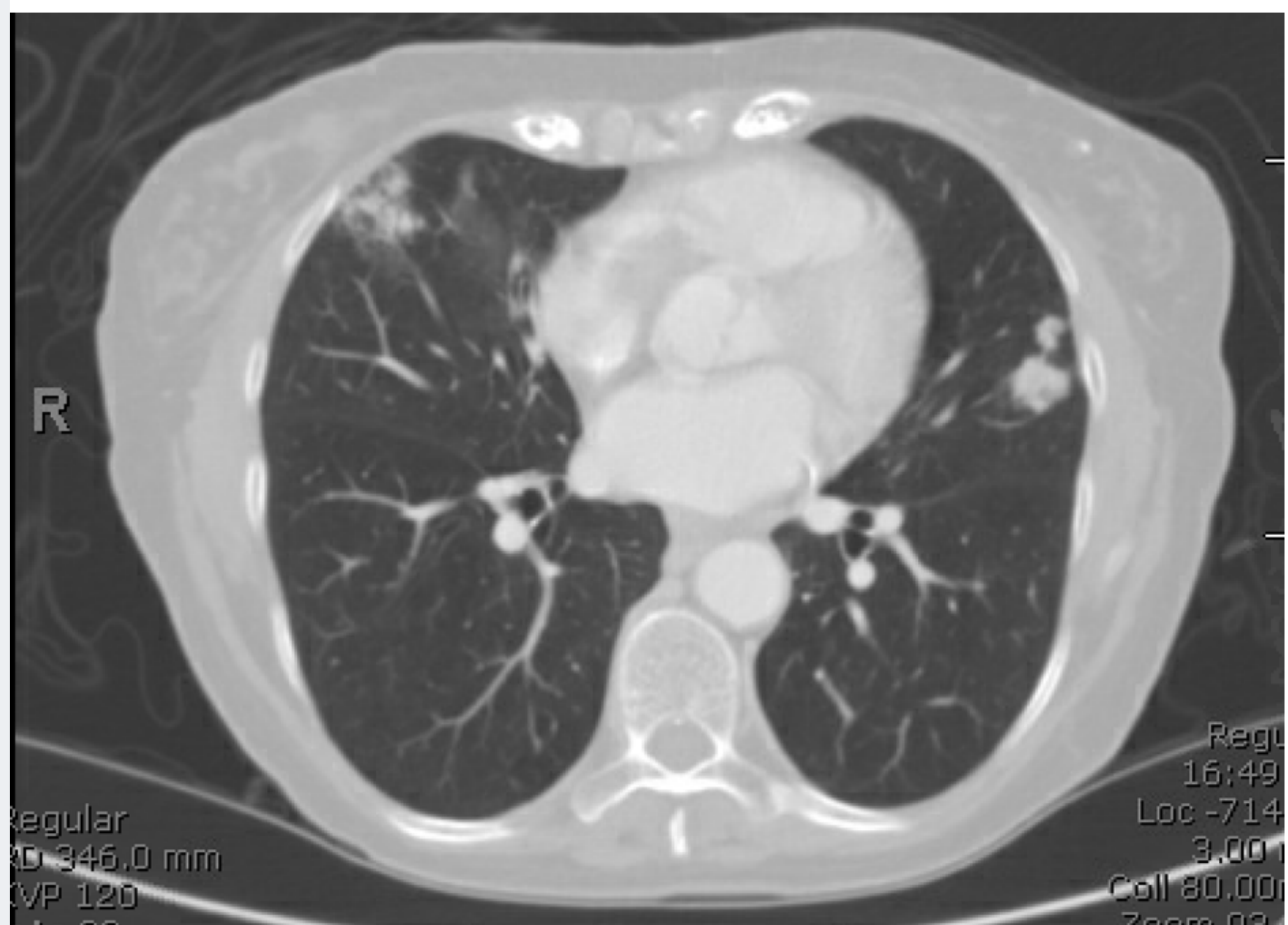Biopsy and NGS of left lingular nodule demonstrated adenocarcinoma KRAS G12C mutation, TP53 mutated, PDL1 60%.

The pathology and NGS from the RML nodule revealed: well differentiated adenocarcinoma, STK11 mutation, PD-L1 negative.

## TESTING

### CT-CHEST W/CONTRAST

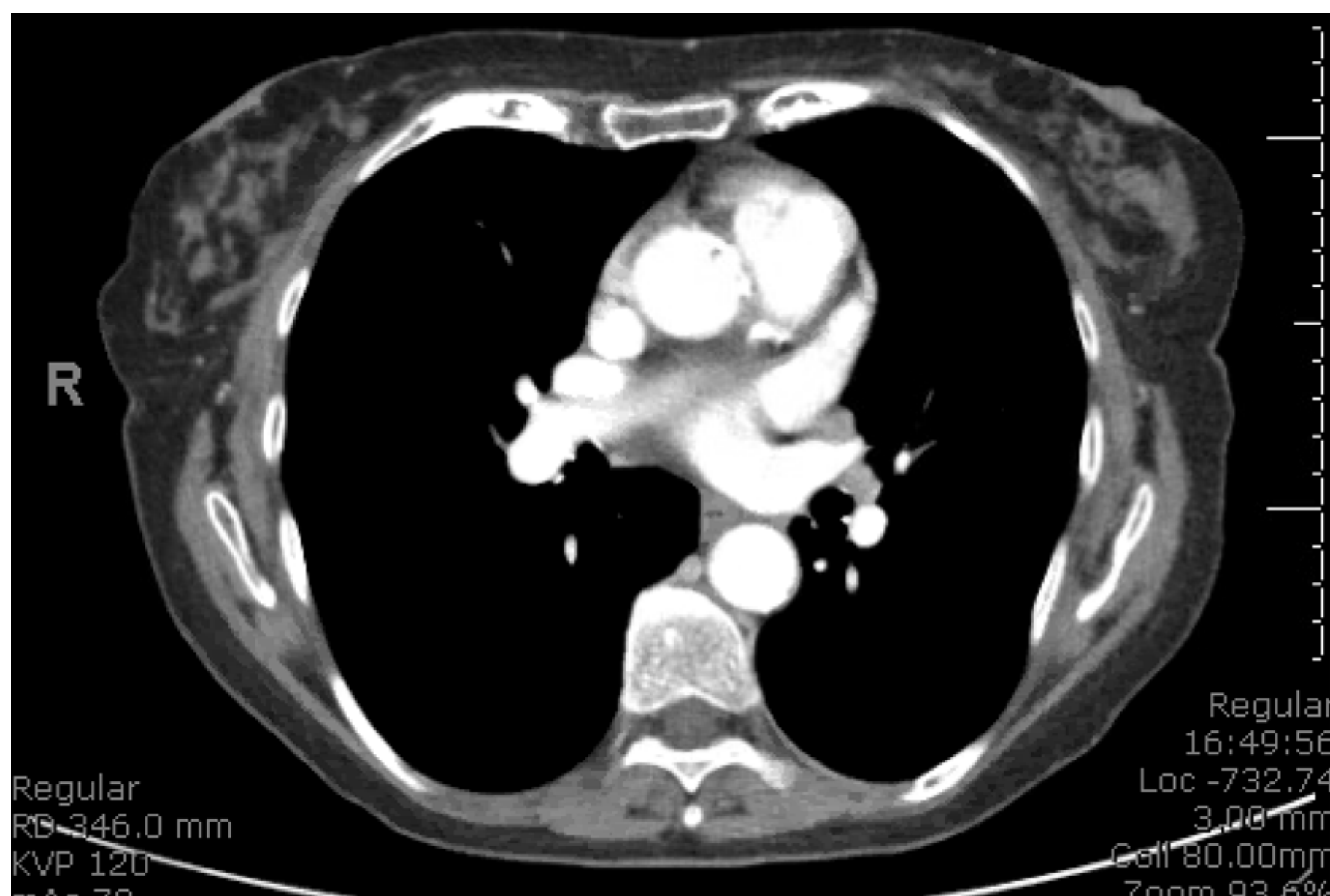
- 1.4 x 1.5 cm solid nodule in the left lingula.
- 2.2 x 1.2 cm. mass in the right middle lobe, described as ground glass in appearance.
- Two small L hilar nodes on mediastinal window.





# THE AMAZING CASE RACE

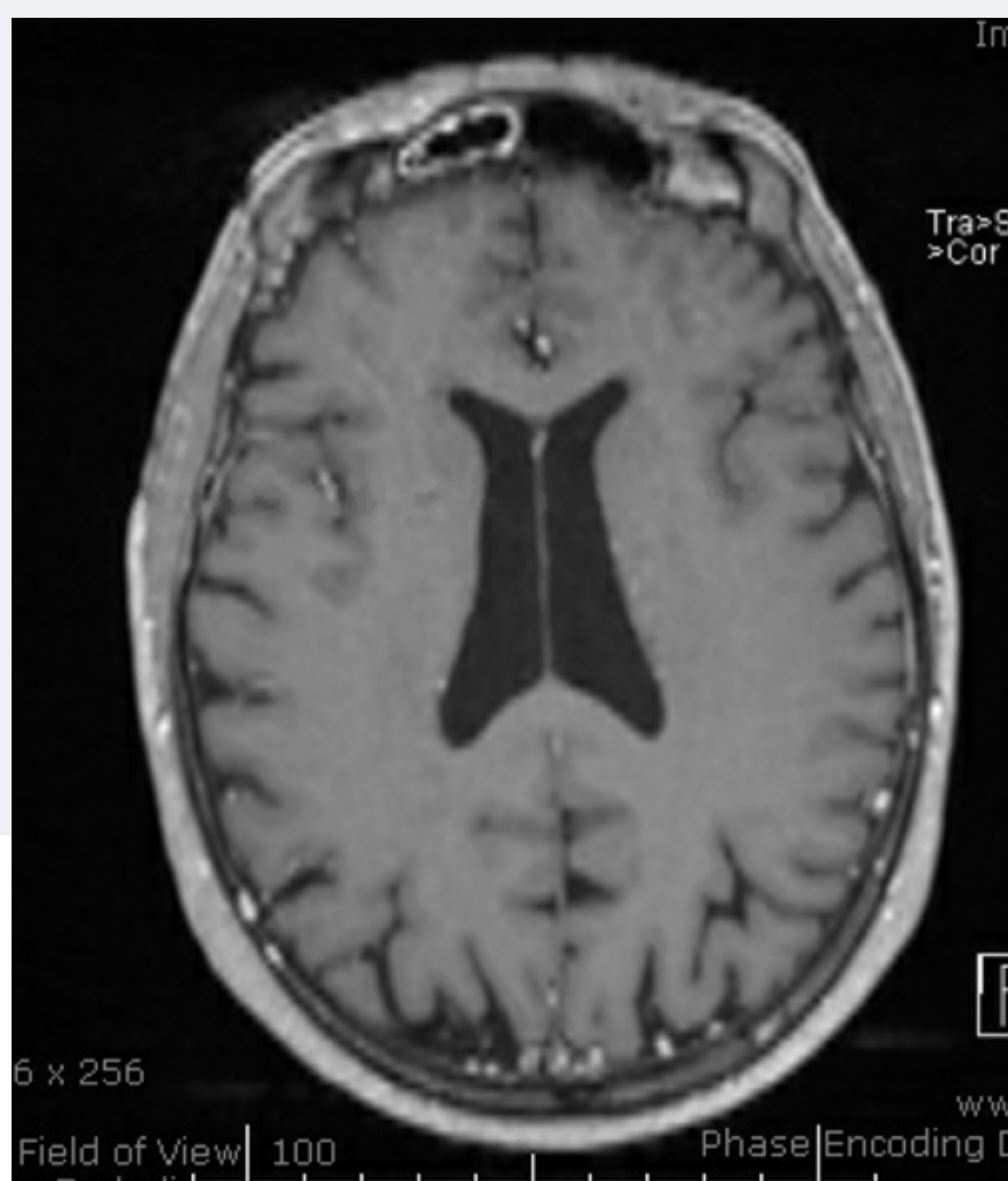
## CASE STUDY 11



## ADDITIONAL TESTING

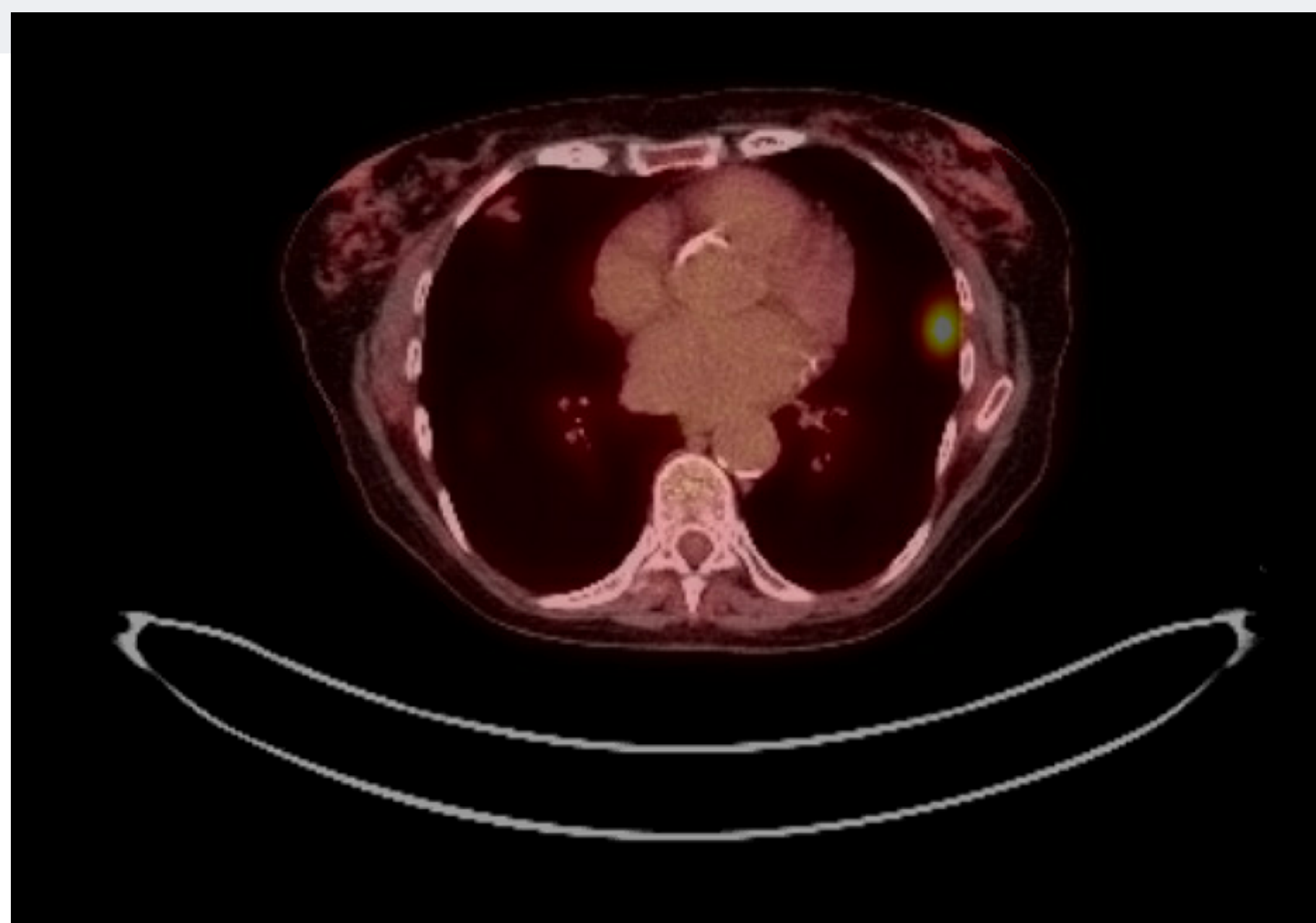
## PET SCAN

- Hypermetabolism in the L lingular nodule (SUV 6.7) and the left hilum.
- Minimal hypermetabolism of the RML ground glass nodule.
- Given the differing CT and PET findings between the bilateral nodules, bilateral primary lung cancers were suspected.



## BRAIN MRI

- No evidence of brain metastasis.






COMPLICATION  
CONSIDERATIONS

# Want to learn more about this case?

**VOTE FOR CASE 11**



Scan showed an irregular soft tissue mass measuring 9.3 x 4.7 x 7.1 cm seen centered in the upper lobe abutting the mediastinal pleura, involving the left perihilar region and superior segment of left lower lobe with multiple satellite nodules scattered in both lungs. Small left pleural effusion. There are also enlarged mediastinal, left hilar and left supraclavicular lymph nodes..

Figure 3