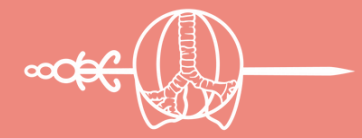

THE AMAZING CASE RACE

CASE STUDY 17

2023 ACADEMY

IASLC



INTERNATIONAL
ASSOCIATION
FOR THE STUDY
OF LUNG CANCER

A case of recurrent ROS-1 fusion cancer.

Melinda Hsu, MD, MS
United States

LEARNING GOALS

Goal 1: Choose appropriate workup and testing for recurrence of locally advanced non-squamous NSCLC.

Goal 2: Recognize the need for biopsy and biomarker testing at progression.

Goal 3: Choose appropriate first-line treatment for ROS-1 fusion cancer.

Goal 4: Manage allergic reaction to targeted therapy.

BACKGROUND

M.C. is a 56-year -old with a remote history of cervical cancer (19 yo) s/p partial hysterectomy who just moved to Wisconsin.

One year ago, she was found to have a 8cm lesion of the RLL with paratracheal and hilar lymphadenopathy

She was ultimately diagnosed on EBUS with T4N2M0 NSCLC adenocarcinoma, PD-L1 60%, reportedly no targetable mutations.

She presents to establish care after her move.

THE AMAZING CASE RACE

CASE STUDY 17

CURRENT PRESCRIPTIONS

- No medications.

COMORBIDITIES/MED HX

- Cervical cancer (19yo)
- Hysterectomy (32yo)
- Bilateral knee replacements (~10 years)

OVERALL DIAGNOSIS

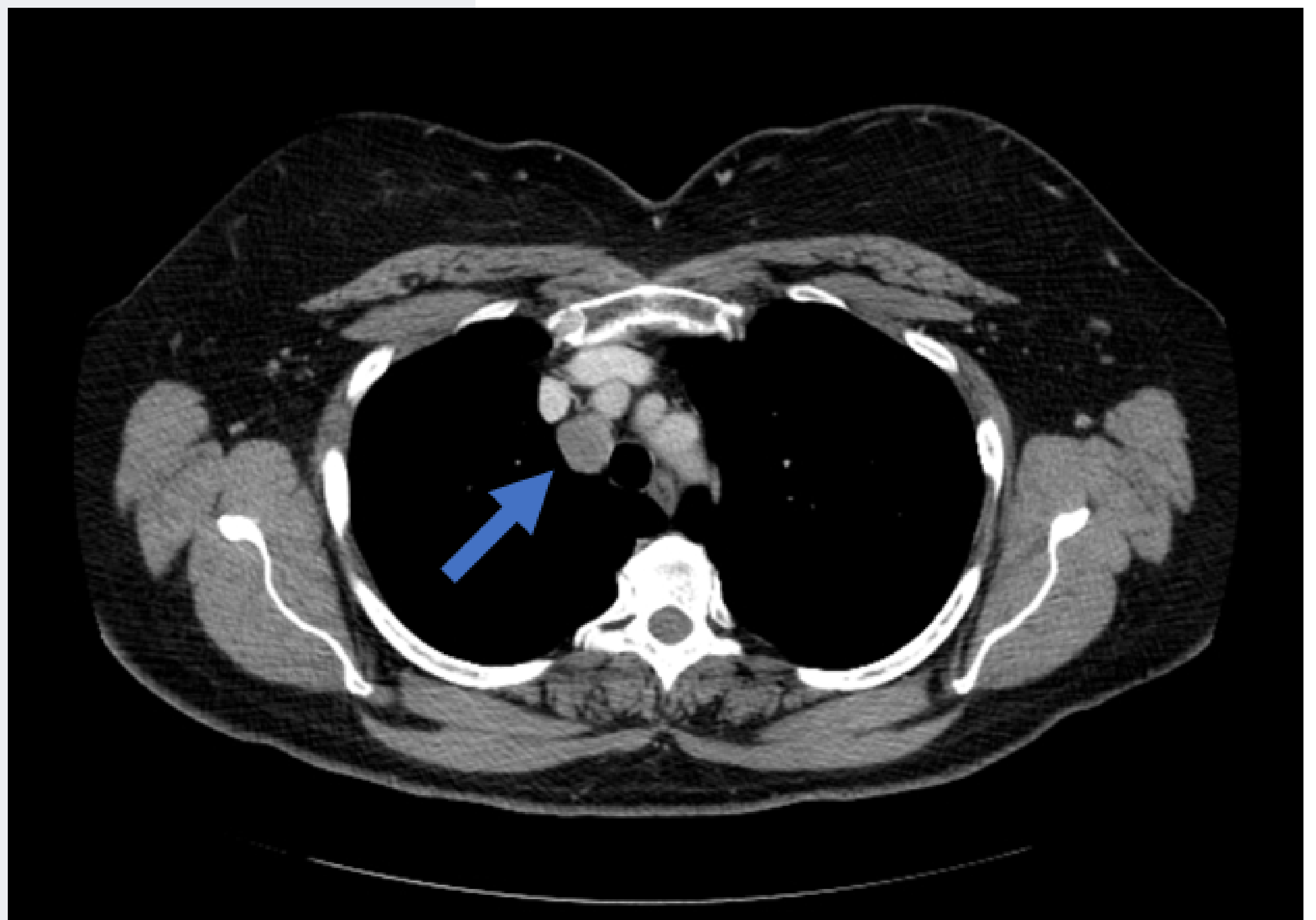
cT4 pN2 cM0 NSCLC adenocarcinoma of the RLL

PD-L1 60%

Notes from outside hospital report '*no targetable mutations*'.

TESTING

- New Chest CT reveals a new, enlarged right upper paratracheal lymph node.



THE AMAZING CASE RACE

CASE STUDY 17

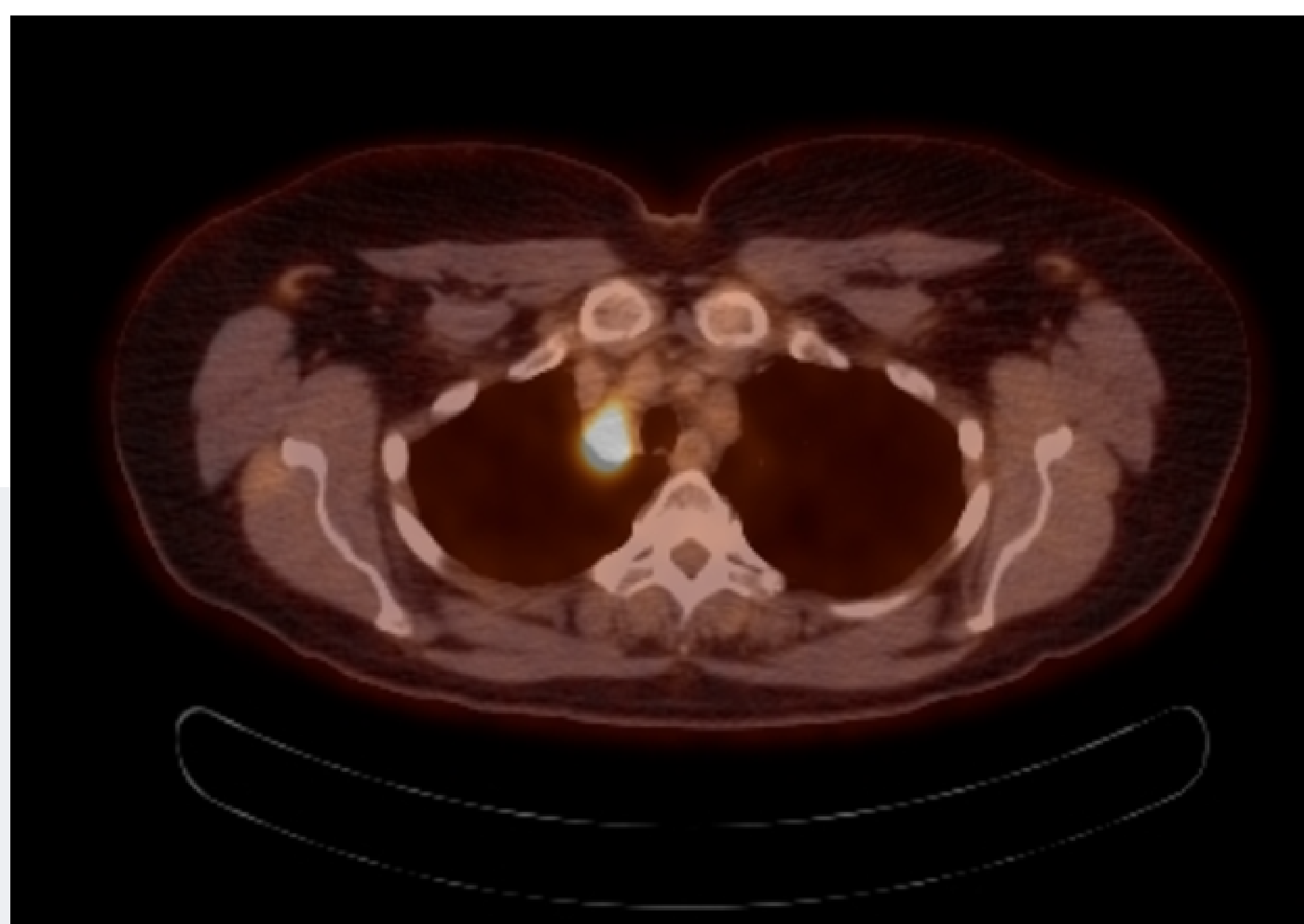
IASLC



INTERNATIONAL
ASSOCIATION
FOR THE STUDY
OF LUNG CANCER

TREATMENT CONSIDERATIONS

- Patient was treated with concurrent chemotherapy and radiation with weekly carboplatin and paclitaxel, followed by one dose of consolidation durvalumab, which was stopped for pneumonitis.



There is a hypermetabolic superior right paratracheal lymph node (max SUV 9.8) measuring 2.2 cm. In addition, there is a mildly hypermetabolic subcentimeter subaortic lymph node (max SUV 4.3).

**Want to learn more
about this case?**

VOTE FOR CASE 17